

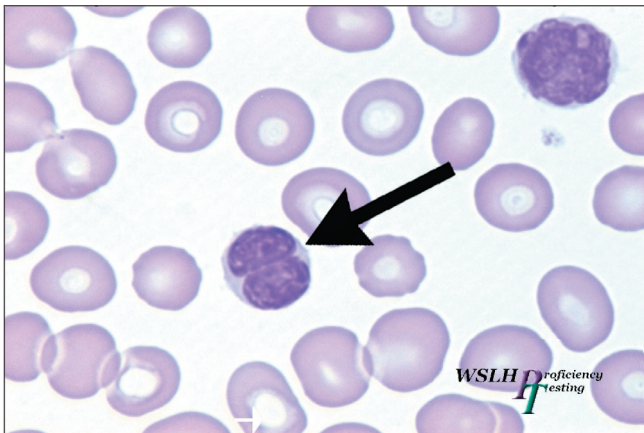
CASE HISTORY

Images XI04-3-1 through 6 come from a 59 year old male presenting with heavily itching erythroderma on his trunk and extremities. He had no relevant past medical history. A skin biopsy was ordered. CBC and other lab results are listed below:

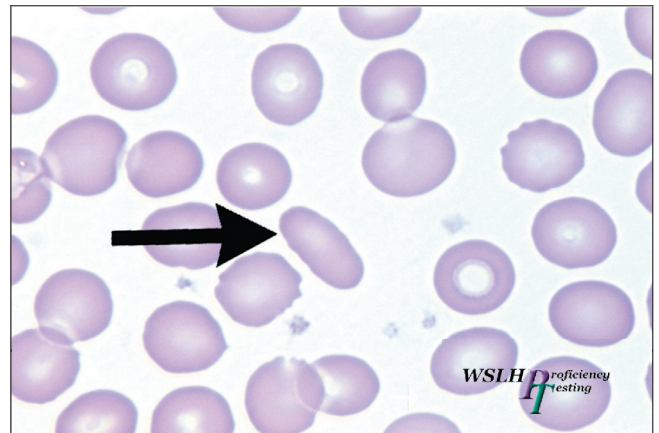
WBC	20.0 x10 ⁹ /L	Differential:	RBC	4.80 x 10 ¹² /L	MCV	94.3 fL	PLT	130 x 10 ⁹ /L
		Neut	HgB	15.1 g/dL	MCHC	33.3 g/dL	MPV	7.4 fL
		Lym	HCT	45.3 %	RDW	26.4 fL		
		Mono						
		Eo						
		Baso						

Lymphocyte phenotyping: CD2, CD3, CD4, and CD5 positive
 CD7, CD8, and CD25 negative

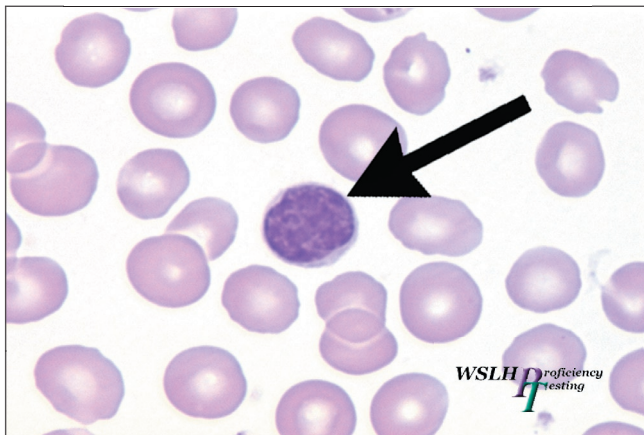
Unless noted otherwise, all images are taken from **Wright's stained peripheral blood** at a total magnification of 1000X.



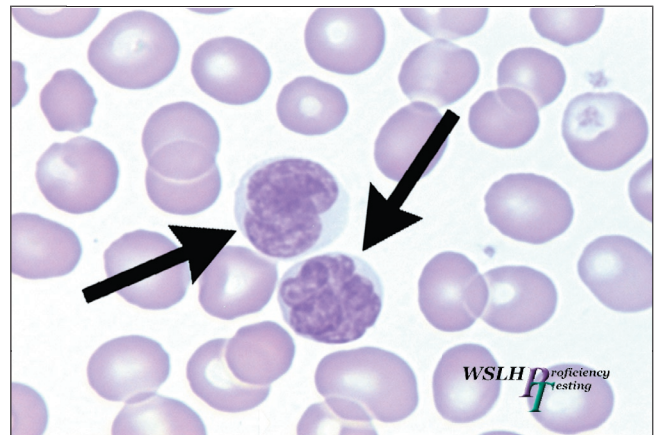
XI04-3-1



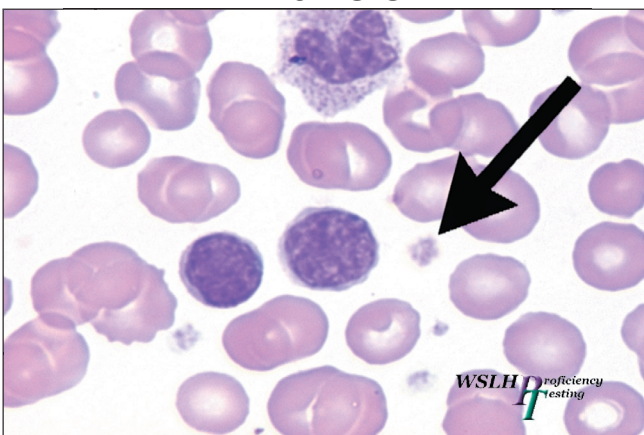
XI04-3-2



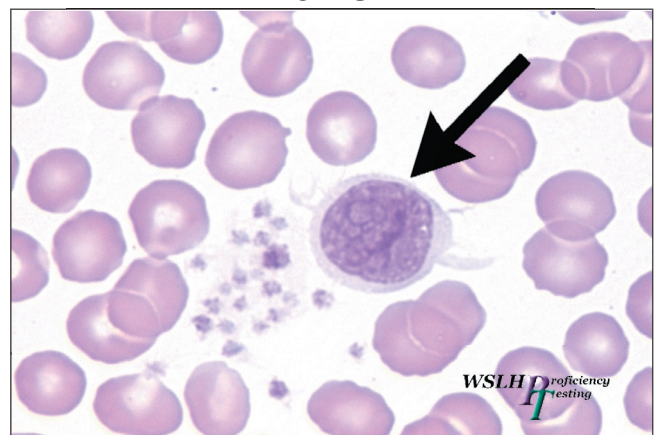
XI04-3-3



XI04-3-4



XI04-3-5



XI04-3-6