Case study: TB/MAC Coinfection

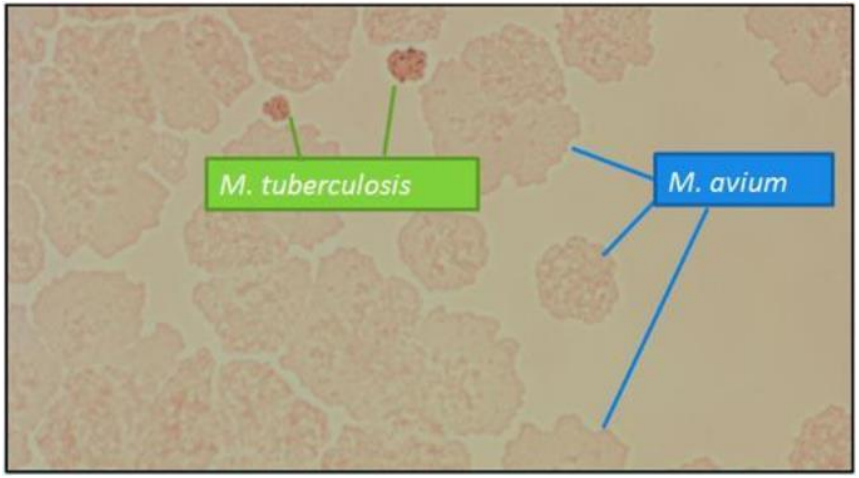

Donald Busalacchi B.S.
Microbiologist- WSLH

Case Study

- 47 year old male
- Born in India, arrived in US in 2012

Jan 2018

- Presenting with fever, chills, night sweats and cough >3weeks
- Chest X-Ray= Evidence of cavitary disease
- TST positive

Case Study

- Sputum collected 1/6/18.
  - smear positive → WSLH
- TB PCR= +, MAC= Equivocal on 10/10/18
  - Patient placed in respiratory isolation
  - Started on RIPE therapy
- Contact investigations conducted in two counties

14 Sputum specimens collected over 3+ months

1/6/18

1/12/18

1/13/18

1/14/18

2/9/18

2/10/18

2/11/18

2/25/18

3/4/18

3/11/18

3/25/18

4/8/18

4/2/18

4/15/18

14 Sputum specimens collected over 3+ months

1/6/18	2/25/18
1/12/18	3/4/18
1/13/18	3/11/18
1/14/18	3/25/18
2/9/18	4/8/18
2/10/18	4/2/18
2/11/18	4/15/18

Sputum collected 1/6/18

1/11-TB PCR= +, MAC= Equivocal

- Start a seed vial for 1st line DST
- Patient placed in respiratory isolation
- Started on RIPE therapy

1/12-Perform GeneXpert in house

- Result is “likely rifampin susceptible”

1/16- 1st grew in 2d 18h(too fast)

- TB PCR=19.81, MAC PCR=0
- Started a new S.V. from which DST was setup.

Sputum collected 1/6/18

1/29- All drug tubes are coming up as Resistant

- No visible contamination
- Resistant drug tubes subbed to 7H11 & BAP.
- Set to CDC for MDDR, full agar proportion.
- Start a new S.V. from single isolated colony of TB.

2/6- MALDI on 7H11 from drug tubes = MAC.

- All PCR+ for TB &MAC

2/7- MDDR predicts pan susceptibility

- 1 silent mutation in pncA

Results for Molecular Detection of Drug Resistance (Sanger Sequencing, complete panel); Conventional Drug Susceptibility Test in progress.

cus (region) examined*	Result	Interpretation (based on in-house evaluation of 550 clinical isolates)
B (RRDR)	No mutation	Probably Rifampin susceptible. (97% of RMP-R isolates in our in-house evalua 550 clinical isolates have a mutation at this locus.)
A (promoter)	No mutation	Cannot rule out INH resistance. (86% of INH-R isolates in our in-house evaluat 550 clinical isolates have a mutation at one or both of these loci.)
G (Ser315 codon)	No mutation	
bB (Met306,Gly406)	No mutation	Cannot rule out ethambutol resistance. (79% of EMB-R isolates in our in-house evaluation of 550 clinical isolates have a mutation at this locus.)
cA (promoter, coding region)	**Silent Mutation:** TCC>TCT; Ser65Ser	Cannot rule out PZA resistance. (86% of PZA-R isolates in our in-house evalu of 550 clinical isolates have a mutation other than the one detected at this locus The mutation detected is a synonymous (silent) single-nucleotide polymorphism (SNP) which does not result in an amino acid change. It is not considered clinic significant.
rA (QRDR)	No mutation	Cannot rule out fluoroquinolone resistance. (80% of FQ-R isolates in our in-hou evaluation of 550 clinical isolates have a mutation at this locus.)
(1400 region)	No mutation	Cannot rule out resistance to injectable drugs (kanamycin, capreomycin, amika (In our in-house evaluation of 550 clinical isolates: • 91% of AMK-R isolates have a mutation in the rrs locus; • 87% of KAN-R isolates have a mutation in either the rrs locus or the eis lo • 55% of CAP-R isolates have a mutation in either the rrs locus or the tlyA lo
(promoter)	No mutation	
A (entire ORF)	No mutation	

Sputum collected 1/6/18

2/12- Isolate both TB & MAC, report out mixed culture.

2/22- Report out 1st line DST. Pan-susceptible.

- Ethambutol stopped at this time
- Final PZA dose on 3/16/18
- IHN and Rif 9 months.

3/2- Final Report agar proportion from CDC

- "Specimen contaminated unable to perform susceptibility testing"

14 Sputum specimens collected over 3+ months

1/6/18

1/12/18

1/13/18

1/14/18

2/9/18

2/10/18

2/11/18

2/25/18

3/4/18

3/11/18

3/25/18

4/8/18

4/2/18

4/15/18

14 Sputum specimens collected over 3+ months

1/6/18

1/12/18

1/13/18

1/14/18

2/9/18

2/10/18

2/11/18

2/25/18

3/4/18

3/11/18

3/25/18

4/8/18

4/2/18

4/15/18

Sputa collected 1/12, 1/13, 1/14

- 4+ smear positive
- Cultures positive for M.tbc with good TB growth on solid media
- MAC not present.

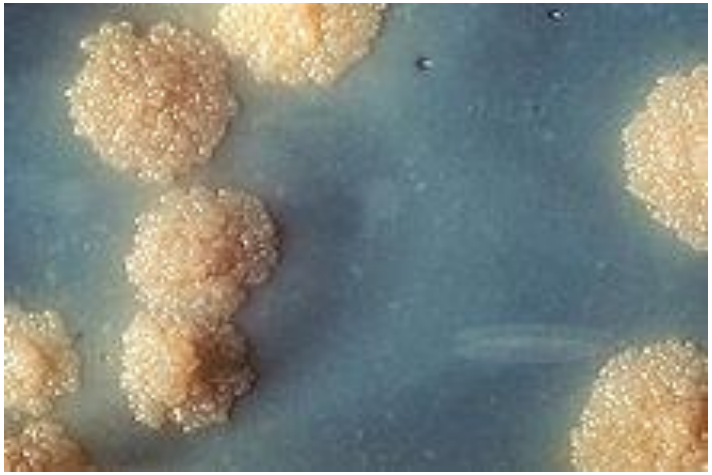

14 Sputum specimens collected over 3+ months

1/6/18

1/12/18

1/13/18

1/14/18

2/9/18

2/10/18

2/11/18

2/25/18

3/4/18

3/11/18

3/25/18

4/8/18

4/2/18

4/15/18

14 Sputum specimens received over 3+ months

1/6/18

1/12/18

1/13/18

1/14/18

2/9/18

2/10/18

2/11/18

2/25/18

3/4/18

3/11/18

3/25/18

4/8/18

4/2/18

4/15/18

Sputa collected 2/9, 2/10, 2/11

- 4+ smear positive
- Cultures positive for both TB & MAC
- Able to isolate both species from solid media

14 Sputum specimens collected over 3+ months

1/6/18

1/12/18

1/13/18

1/14/18

2/9/18

2/10/18

2/11/18

2/25/18

3/4/18

3/11/18

3/25/18

4/8/18

4/2/18

4/15/18

14 Sputum specimens collected over 3+ months

1/6/18	2/25/18
1/12/18	3/4/18
1/13/18	3/11/18
1/14/18	3/25/18
2/9/18	4/8/18
2/10/18	4/2/18
2/11/18	4/15/18

Sputum collected 2/25/18

- 2+ smear positive
- TB PCR= 28.75, MAC PCR=32.82
- Cording TB-like colonies seen, unable to isolate away from MAC.

14 Sputum specimens collected over 3+ months

1/6/18

1/12/18

1/13/18

1/14/18

2/9/18

2/10/18

2/11/18

2/25/18

3/4/18

3/11/18

3/25/18

4/8/18

4/2/18

4/15/18

14 Sputum specimens collected over 3+ months

1/6/18

1/12/18

1/13/18

1/14/18

2/9/18

2/10/18

2/11/18

2/25/18

3/4/18

3/11/18

3/25/18

4/8/18

4/2/18

4/15/18

Sputum collected 3/4/18

3/16-Culture flags positive

- TB PCR=30.38 MAC PCR=31.26 (4+ smear)

3/19- Repeat PCRs

- TB PCR= 31.03 MAC= 25.44
- Report out MAC

4/16- Terminal PCR

- TB PCR= 37.03
- Patient still in isolation

Sputum collected 3/4/18

4/24- Upon health departments request we sent a supplemental report that no viable TB was detected in sample.

5/1- Patient released from respiratory isolation

Sputum collected 3/11/18

3/22- MGIT Positive

- TB PCR= 29.08, MAC PCR=33.39

4/3- Large colony type growing on solid media

- M. fortuitum by MALDI
- No TB growth seen.

4/30- Terminal TB PCR = 29.12

- Reported out as no TB isolated.

14 Sputum specimens collected over 3+ months

1/6/18

1/12/18

1/13/18

1/14/18

2/9/18

2/10/18

2/11/18

2/25/18

3/4/18

3/11/18

3/25/18

4/8/18

4/2/18

4/15/18

14 Sputum specimens collected over 3+ months

1/6/18

1/12/18

1/13/18

1/14/18

2/9/18

2/10/18

2/11/18

2/25/18

3/4/18

3/11/18

3/25/18

4/8/18

4/2/18

4/15/18

- Remaining specimens all negative for viable TB
- We continue to detect TB DNA via PCR w/out evidence of growth.


Collection Date
12/31/2017
1/20/2018
2/9/2018
3/1/2018
3/21/2018
4/10/2018
4/30/2018
18
20
22
24
26
28
30
32
34
36
CT vaule
TB CT
MAC CT
Linear (TB CT)

Case Study

June 2018

- CXR shows marked clinical improvement
- Excellent response to abx treatment
- Originally scheduled to complete 9 month treatment in Mid-October.
- Patient Moving to MD for work.

Case Study

August 2018

- Patient experiencing a variety of pain in neck, back, left shoulder
- Episodic chest tightness and shortness of breath
- Dr. ordered a chest CT
- diagnosed with Pott's disease.

Pott's Disease

- Postural orthostatic tachycardia syndrome(Tuberculosis spondylitis)
- A form of TB occurring in the vertebrae
- Typically caused by extra spinal infection; however, Disks are vascularized in children and thus can be primary site of infection.
- Progression can lead to kyphotic deformity, resulting from vertebral collapse.
- Other possible effects include: compression fractures and neurological damage, such as paraplegia.
- Usually responds well to standard 4-Drug treatment

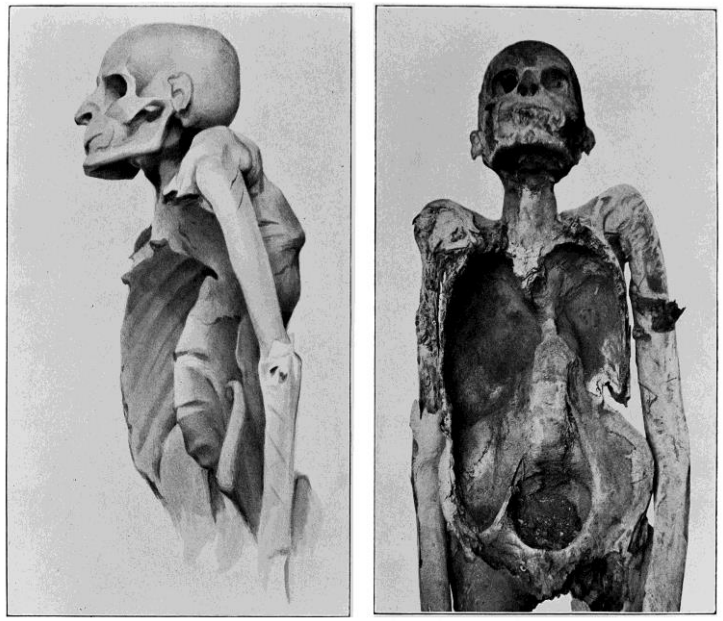

Case Study

- Currently being treated by Maryland public health department.
- INH and RIF treatment extended to 12 months
- Patient gaining weight and looks well
- Responding very well to Pott's treatment
- Additional sputum specimens collected
  - Smear negative
  - No culture growth so far

Questions?

Thank you